

Intrathoracic fracture-dislocation of the humeral head: a case report

Juan F Abellan, Eduardo Melendreras, Diego J Gimenez, Francisco J Carrillo, Luis Ruano, Jorge Rivkin
Department of Orthopedics and Trauma Surgery, Hospital Morales Meseguer, Murcia, Spain

ABSTRACT

Fracture-dislocation of the humeral head into the thoracic cavity is a rare injury. We present one such case in a 70-year-old woman. She presented with a 4-part fracture-dislocation of the proximal humerus, with displacement of the humeral head into the thoracic cavity. She had no signs of acute distress or hemodynamic instability. She underwent hemiarthroplasty of the right shoulder, but the humeral head fragment could not be removed. At 27-month follow-up, the patient had limited mobility of her right shoulder due to axillary nerve palsy but no pain or intrathoracic complications. In the absence of intrathoracic complications, the removal of the humeral head may not be necessary.

Key words: *shoulder dislocation; shoulder fractures; thoracic cavity*

INTRODUCTION

Fracture-dislocation of the humeral head into

the thoracic cavity is a rare injury, and there is no consensus on its treatment. We report the presentation and management of this injury in a 70-year-old woman.

CASE REPORT

In February 2004, a 70-year-old woman was admitted to the emergency department with severe pain in both upper and lower right limbs and difficulty in breathing after being hit by a car. The patient had no signs of acute distress. Her Glasgow Coma Scale score was 15. She was haemodynamically stable, with a heart rate of 95 beats/min, a respiratory rate of 14 breaths/min, and a systolic blood pressure of 130 mm Hg. There was swelling of her right shoulder and upper hemithorax, but no crepitus on movement. The right lower limb appeared shortened and in external rotation. Vascular examination of both upper and lower limbs was normal: radial, femoral, popliteal, and distal pulses were all 2+. Neurological examination of her hand and forearm revealed a loss of proximal motor function and sensation in the axillary nerve distribution.

Radiography and computed tomography of the

chest, right shoulder, pelvis and right lower limb revealed a Schatzker II tibial plateau fracture, an intertrochanteric fracture, fractures of the second to sixth right ribs, and a 4-part fracture-dislocation of the proximal humerus, with intrathoracic displacement of the humeral head, and a moderate haemothorax (Fig. a).

She was taken to the intensive care unit despite being clinically and haemodynamically stable. A chest tube was inserted for drainage of the haemothorax. Non-external ventilatory support was given. On day 5 after admission, the patient underwent internal fixation for the tibial plateau fracture (using 2 AO/ASIF screws) and the proximal femoral fracture (using a gamma nail). She also

underwent hemiarthroplasty of the proximal humerus via a deltopectoral approach, but the humeral head fragment could not be extracted through the path of the dislocation. As the patient had no intrathoracic complications (cardiorespiratory symptoms, vascular or neural injury), open thoracic surgery was not performed and the humeral head fragment was not removed.

The postoperative course of the patient was uneventful. Physical therapy was started on day 4. She developed an axillary nerve palsy, with weakness in flexion, extension and abduction of the right shoulder. She was discharged 20 days after admission.

At 6-month follow-up, the patient still

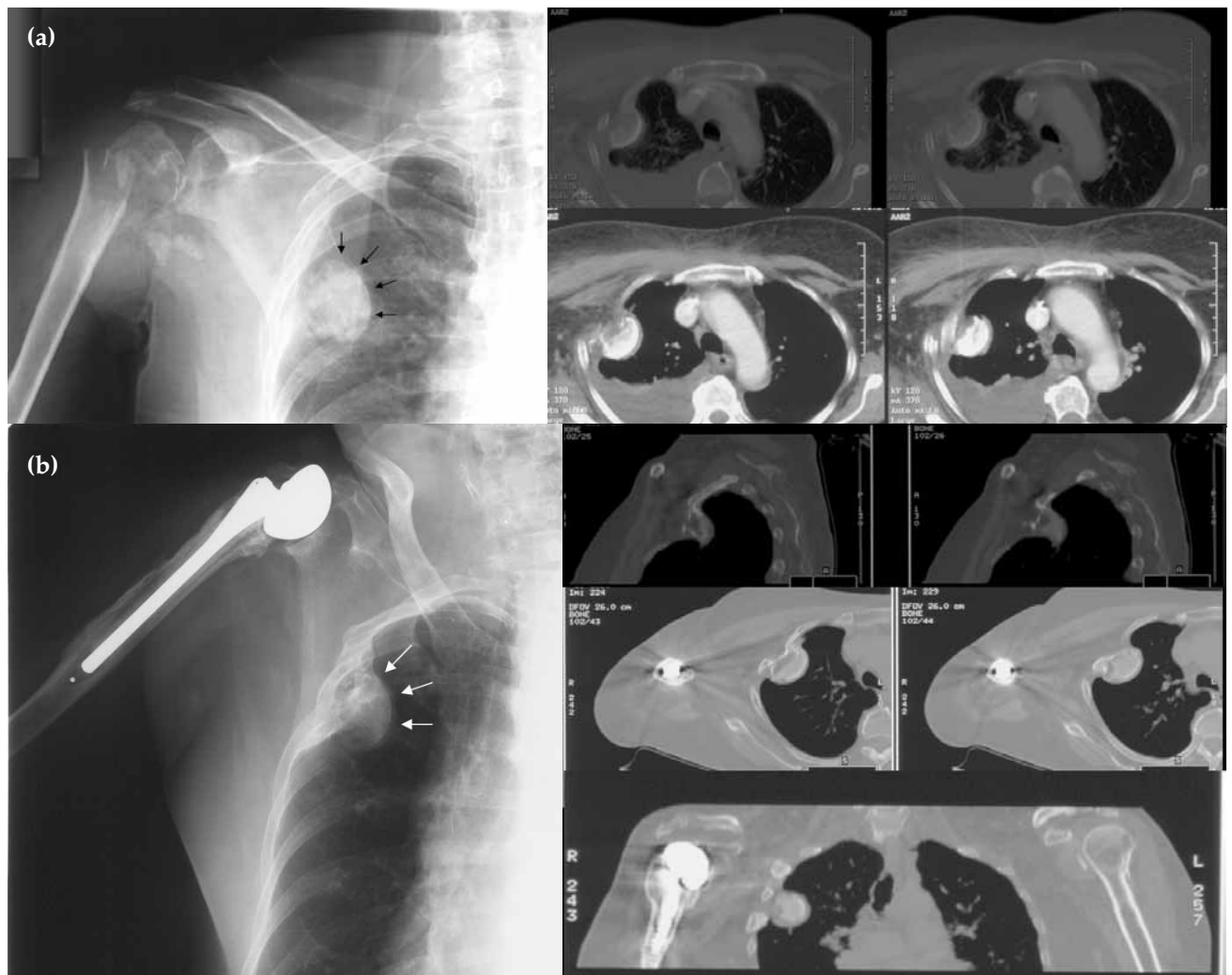


Figure Radiography and computed tomography of the chest showing (a) a proximal humerus fracture, displacement of the humeral head into the right lung field (arrows), and a moderate haemothorax. (b) At 27-month follow-up, there is no change in size or location of the intrathoracic humeral head (arrows) since initial imaging and no evidence of pulmonary complications.

demonstrated weakness in her right shoulder movements. An electromyography showed severe partial axonotmesis of the right axillary nerve in the acute stage, without electromyographic signs of neural regeneration.

In the final follow-up at 27 months, the patient reported minor limitations in her activities of daily living (despite axillary nerve palsy) and had no pain or intrathoracic complications, although the humeral head fragment remained in her hemithorax. The size and location of the humeral head fragment had not altered (Fig. b).

DISCUSSION

Four-part fracture-dislocation of the proximal humerus, with intrathoracic displacement of the humeral head, is a rare injury. Only a few such cases have been reported. Of these patients, 5 were older than 60 (mean, 72; range, 65–79) years, and the injury mechanism was falling down stairs^{1–5}; another 5 were younger than 60 (mean, 38; range, 18–58) years, and the injury mechanism was high-energy trauma (motor vehicle accidents) and a fall from a horse.^{6–10}

There are also reports of displacement of the humeral head into the contralateral hemithorax¹¹ and the retroperitoneal space,¹² and intrathoracic dislocation of the proximal humerus, with avulsion of a large fragment from the greater tuberosity.^{13,14}

There is no consensus on treatment for this injury; each case must be evaluated independently to choose the most appropriate treatment approach. Two case reports of patients aged 74 and 79 years, respectively, document the use of immobilisation and early rehabilitation without removal of the humeral head fragment, as the patients were unfit for surgery.^{3,5} Despite loss of shoulder mobility, their activities of daily living were not affected and they had no intrathoracic complications.

With regard to operative treatments, open surgery to remove the humeral head and reattach the rotator cuff to the proximal humeral shaft has

been reported.¹ At 2-year follow-up, the patient had no pain, had regained 50% of shoulder function, and was satisfied with the functional outcome. Reattachment of the humeral head to the shaft using a plate has also been reported in 3 patients with mixed outcome.^{6,7,12} Two of the patients subsequently developed avascular necrosis of the humeral head, and the humeral plate and screws were removed.^{7,12} The remaining patient showed no evidence of loss of reduction or avascular necrosis at one-year follow-up.⁶ This treatment is a valid option, especially in young patients. Other treatments such as resection arthroplasty or 'skillful neglect' can also be a valid option, but can result in a loss of function.

Hemiarthroplasty after removal of the humeral head has been performed for patients with respiratory symptoms^{2,4,8,9} or in those with the humeral head fragment in the upper thoracic outlet, next to important vascular and neural structures.¹⁰ Differing outcomes have been reported; one study reported poor results because of the associated axillary nerve injury²; other studies reported excellent outcomes in terms of range of motion and strength testing.^{4,10}

Locating the humeral head fragment is important in order to decide on the treatment modality. Some authors recommend that the humeral head must be removed, either through the path of the dislocation or via thoracoscopy or even thoracotomy.^{8,9} We suggest that the humeral head fragment can remain in its location. It must be removed, however, if respiratory complications are present or if the fragment could impact on airway patency or could cause damage to neurovascular or other structures.

In our patient, multidisciplinary assessment and treatment was required. The most significant injury in terms of function was the axillary nerve palsy. Neurovascular examination should be performed to determine necessary treatment. Other considerations in treatment planning include the location of the displaced humeral head fragment, whether there are respiratory complications and the functional status of the patient.

REFERENCES

1. Glessner JR Jr. Intrathoracic dislocation of the humeral head. *J Bone Joint Surg Am* 1961;43:428–30.
2. al-Kaar M, Garcia J, Khan HG, Manueddu C. Intrathoracic dislocation fracture of the head of the humerus [in French]. *J Radiol* 1998;79:57–9.
3. Kaar TK, Rice JJ, Mullan GB. Fracture-dislocation of the shoulder with intrathoracic displacement of the humeral head. *Injury* 1995;26:638–9.
4. Liu HH, Lee YH, Yang SW, Wong CY. Fracture of the proximal humerus with intrathoracic dislocation of the humeral head. *J Trauma* 2007;63:E37–9.

5. Patel MR, Pardee ML, Singerman RC. Intrathoracic dislocation of the head of the humerus. *J Bone Joint Surg Am* 1963;45:1712-4.
6. Anderson M, Rose P, Jacofsky DJ, Torchia ME, Dahm DL. Intrathoracic fracture-dislocation of the proximal humerus: a case report and report of a new surgical technique. *J Trauma* 2007;63:920-3.
7. Hardcastle PH, Fisher TR. Intrathoracic displacement of the humeral head with fracture of the surgical neck. *Injury* 1981;12:313-5.
8. Harman BD, Miller NG, Probe RA. Intrathoracic humeral head fracture-dislocation. *J Orthop Trauma* 2004;18:112-5.
9. Kocer B, Gulbahar G, Aktekin CN, Gunal N, Birinci B, Dural K, et al. Intrathoracic humeral head fracture-dislocation: is removal of the humeral head necessary? *Ann Thorac Surg* 2007;84:1371-2.
10. Wiesler ER, Smith AM, Shilt JS. Humeral head fracture-dislocation into the thoracic outlet: case report and review of the literature. *J Shoulder Elbow Surg* 2004;13:576-9.
11. Eberson CP, Ng T, Green A. Contralateral intrathoracic displacement of the humeral head. A case report. *J Bone Joint Surg Am* 2000;82:105-8.
12. Wirth MA, Jensen KL, Agarwal A, Curtis RJ, Rockwood CA Jr. Fracture-dislocation of the proximal part of the humerus with retroperitoneal displacement of the humeral head. A case report. *J Bone Joint Surg Am* 1997;79:763-6.
13. Simpson NS, Schwappach JR, Toby EB. Fracture-dislocation of the humerus with intrathoracic displacement of the humeral head. A case report. *J Bone Joint Surg Am* 1998;80:889-91.
14. West EF. Intrathoracic dislocation of the humerus. *J Bone Joint Surg Am* 1949;31:61.