

Single-row Versus Double-row Rotator Cuff Repair: Techniques and Outcomes

Joshua S. Dines, MD

Ashesh Bedi, MD

Ncal S. ElAttrache, MD

David M. Dines, MD



Abstract

Double-row rotator cuff repair techniques incorporate a medial and lateral row of suture anchors in the repair configuration. Biomechanical studies of double-row repair have shown increased load to failure, improved contact areas and pressures, and decreased gap formation at the healing enthesis, findings that have provided impetus for clinical studies comparing single-row with double-row repair. Clinical studies, however, have not yet demonstrated a substantial improvement over single-row repair with regard to either the degree of structural healing or functional outcomes. Although double-row repair may provide an improved mechanical environment for the healing enthesis, several confounding variables have complicated attempts to establish a definitive relationship with improved rates of healing. Appropriately powered rigorous level I studies that directly compare single-row with double-row techniques in matched tear patterns are necessary to further address these questions. These studies are needed to justify the potentially increased implant costs and surgical times associated with double-row rotator cuff repair.

- Resultados clínicos similares a las reparaciones abiertas o mini-open
 1. Buess E, Steuber KU, Waibl B: Open versus arthroscopic rotator cuff repair: A comparative view of 96 cases. *Arthroscopy* 2005;21:597-604.
 2. Verma NN, Dunn W, Adler RS, et al: All-arthroscopic versus mini-open rotator cuff repair: A retrospective review with minimum 2-year follow-up. *Arthroscopy* 2006;22:587-594.
- A pesar de los buenos y excelentes resultados la curación tendinosa es controvertida

- Los porcentajes de curación en ECO o RMN varían entre el 91 % en roturas pequeñas y el 10% en roturas masivas

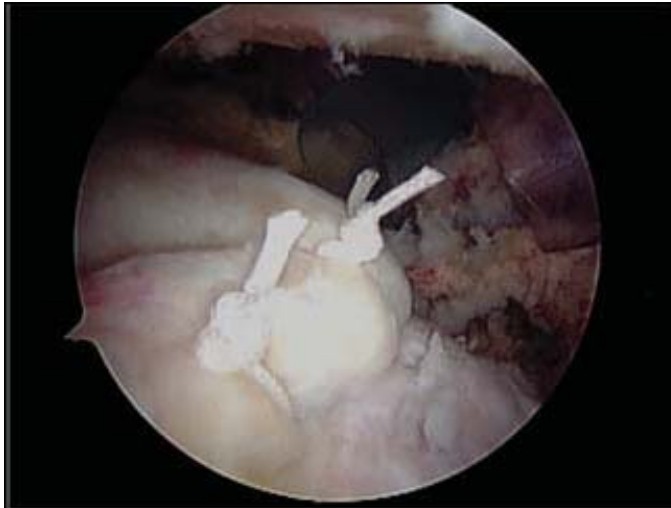3. Galatz LM, Ball CM, Teefey SA, Middleton WD, Yamaguchi K: The outcome and repair integrity of completely arthroscopically repaired large and massive rotator cuff tears. *J Bone Joint Surg Am* 2004;86:219-224.
4. Lafosse L, Brozka R, Toussaint B, Gobezie R: The outcome and structural integrity of arthroscopic rotator cuff repair with use of the double-row suture anchor technique. *J Bone Joint Surg Am* 2007;89:1533-1541.
5. Frank JB, ElAttrache NS, Dines JS, Blackburn A, Crues J, Tibone JE: Repair site integrity after arthroscopic transosseous-equivalent suture-bridge rotator cuff repair. *Am J Sports Med* 2008;36:1496-1503.

- En roturas grandes los buenos resultados se obtienen cuando se consigue la curación tendinosa
 6. Harryman DT II, Mack LA, Wang KY, Jackins SE, Richardson ML, Matsen FA III: Repairs of the rotator cuff: Correlation of functional results with integrity of the cuff. *J Bone Joint Surg Am* 1991;73:982-989.
- La reparación ideal proporciona una fijación inicial fuerte minimizando la separación durante la curación
 7. Gerber C, Schneeberger AG, Beck M, Schlegel U: Mechanical strength of repairs of the rotator cuff. *J Bone Joint Surg Br* 1994;76:371-380.

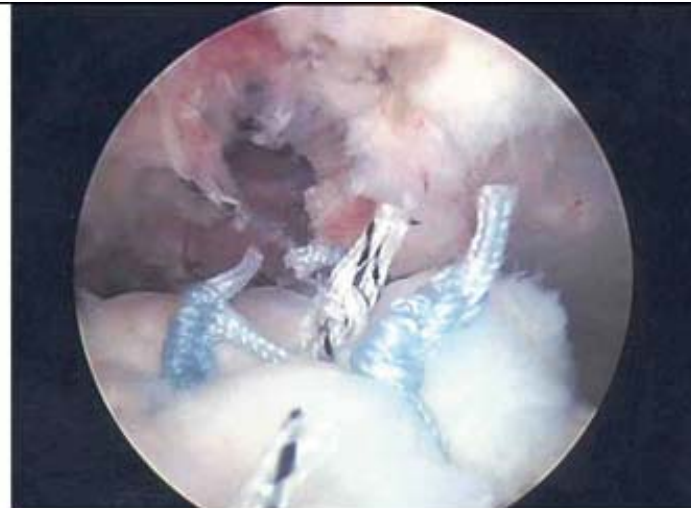- Muchas investigaciones recientes se han centrado en la mejora de la curación tendón-hueso a través de construcciones más fuertes biomecánicamente y un medio biológico mejorado.

8. Lo IY, Burkhart S: Double-row arthroscopic rotator cuff repair: Reestablishing the footprint of the rotator cuff. *Arthroscopy* 2003;19:1035-1042.
9. Park MC, ElAttrache NS, Ahmad CS, Tibone JE: “Transosseous-equivalent” rotator cuff repair technique. *Arthroscopy* 2006;22:1360.e1-5.
10. Dines JS, Grande DA, Dines DM: Tissue engineering and rotator cuff tendon healing. *J Shoulder Elbow Surg* 2007; 16(5 suppl):S204-S207.
11. Kim DH, ElAttrache NS, Tibone JE, et al: Biomechanical comparison of a single-row versus double-row suture anchor technique for rotator cuff repair. *Am J Sports Med* 2006;34:407-414.

- Tradicionalmente se ha usado una hilera simple de implantes colocados en sentido antero-posterior en la tuberosidad.
- Un avance importante en la cirugía artroscópica del manguito es la introducción de técnicas en doble hilera.

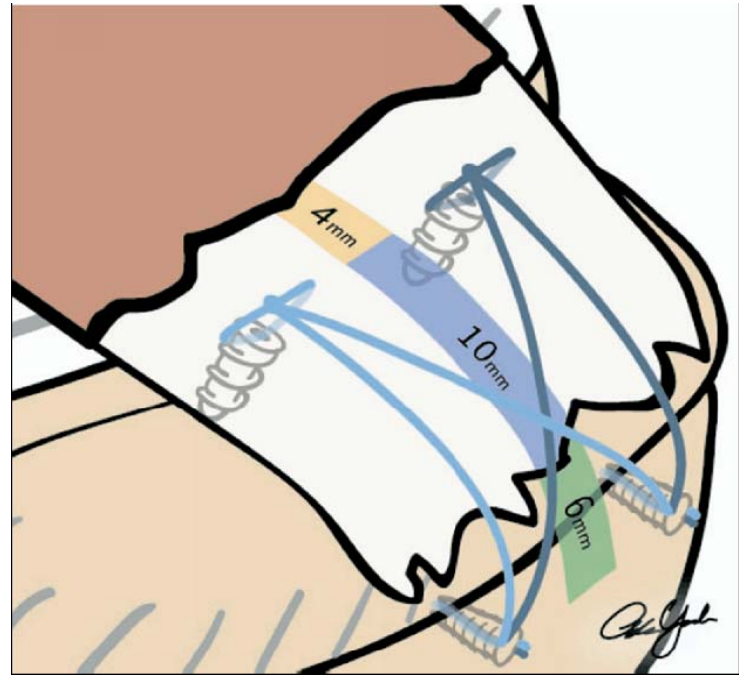
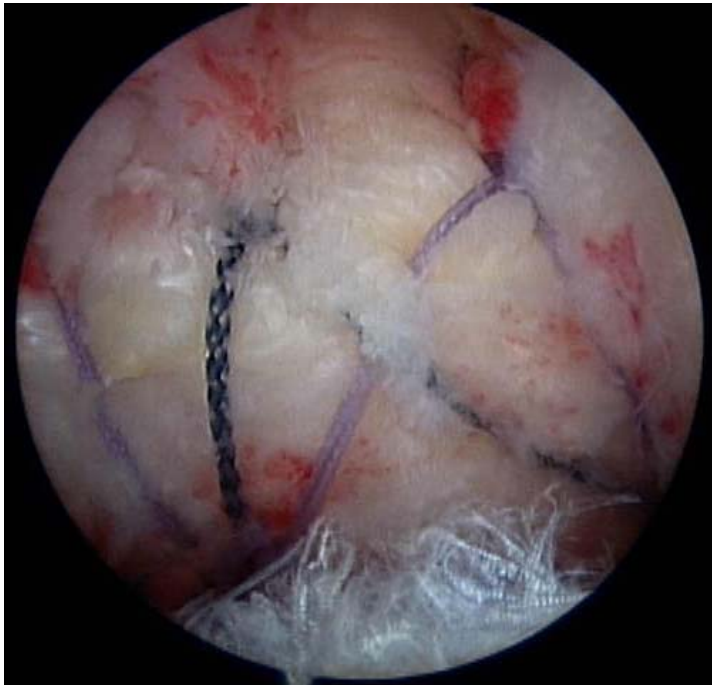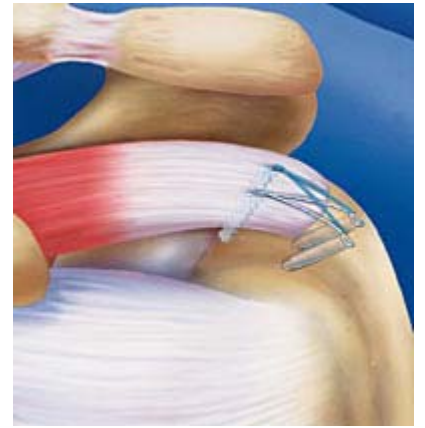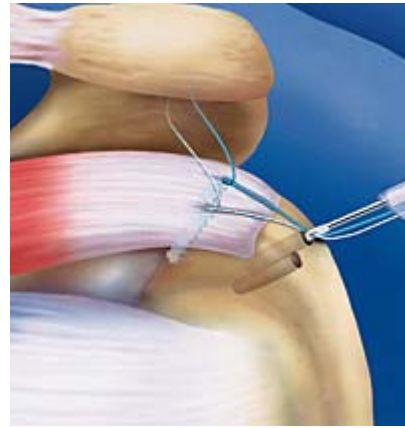
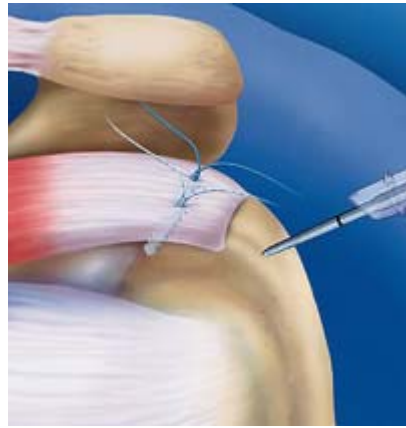


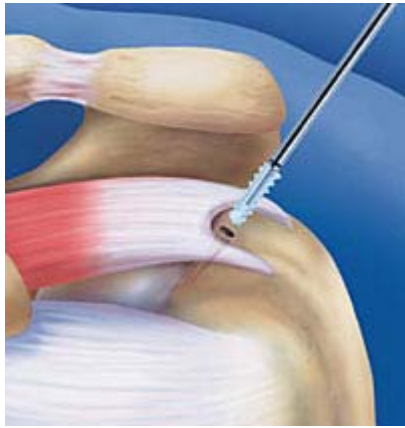A



B

- En las técnicas en doble hilera se coloca una hilera medial en el margen articular, y una segunda fila lateral a la inserción del tendón en la tuberosidad (footprint)
- Superiores propiedades biomecánicas
- Recrea la anatomía normal del footprint
- Mejora la aposición entre el tendón y el hueso
- Fuerza de fijación similar a las técnicas abiertas o de mini-open.

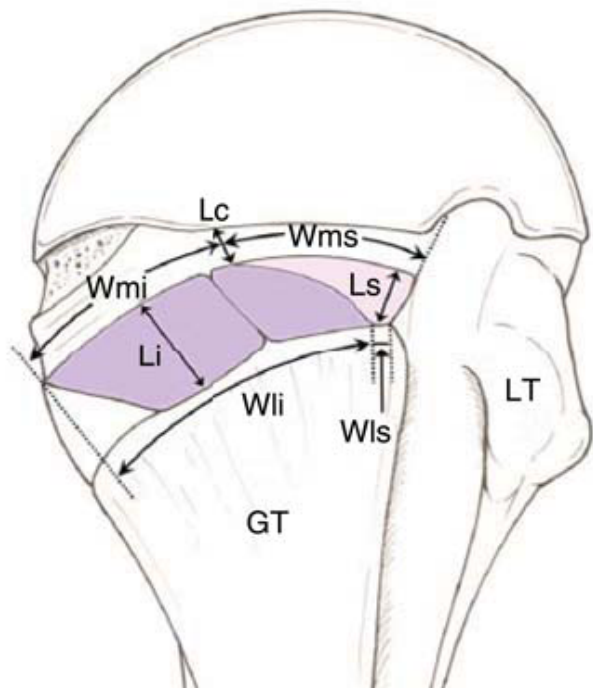


- Estudios comparativos entre la hilera simple y la doble demuestran que esta última presenta:
 - Mayor resistencia a la rotura
 - Mejora de las áreas y presiones de contacto
 - Menor separación durante la curación

12. Smith CD, Alexander S, Hill AM, et al: A biomechanical comparison of single and double-row fixation in arthroscopic rotator cuff repair. *J Bone Joint Surg Am* 2006;88:2425-2431.

13. Meier SW, Meier JD: The effect of double-row fixation on initial repair strength in rotator cuff repair: A biomechanical study. *Arthroscopy* 2006; 22:1168-1173.

14. Meier SW, Meier JD: Rotator cuff repair: The effect of double-row fixation on three-dimensional repair site. *J Shoulder Elbow Surg* 2006;15:691-696.



Average and standard deviation (mm)

Supraspinatus

| | |
|---|------------|
| Maximum medial-to-lateral length | 6.9 ± 1.4 |
| Anteroposterior width of medial margin | 12.6 ± 2.0 |
| Anteroposterior width of lateral margin | 1.3 ± 1.4 |

Infraspinatus

| | |
|---|------------|
| Maximum medial-to-lateral length | 10.2 ± 1.6 |
| Anteroposterior width of medial margin | 20.2 ± 6.2 |
| Anteroposterior width of lateral margin | 32.7 ± 3.4 |

Articular capsule

| | |
|---|-----------|
| Medial-to-lateral length at posterior edge of supraspinatus footprint | 4.5 ± 0.5 |
|---|-----------|

Illustration of the anatomic dimensions of the rotator cuff insertions. The average values of the dimensions are listed. GT = greater tuberosity, Lc = length of attachment of the articular capsule, Li = maximum length of the footprint of the infraspinatus, Ls = maximum length of the footprint of the supraspinatus, LT = lesser tuberosity, Wli = width of the lateral margin of the footprint of the infraspinatus, Wls = width of the lateral margin of the footprint of the supraspinatus, Wmi = width of the medial margin of the infraspinatus, Wms = width of the medial margin of the supraspinatus.

19. Mochizuki T, Sugaya H, Uomizu M, et al: Humeral insertion of the supraspinatus and infraspinatus: New anatomical findings regarding the footprint of the rotator cuff. *J Bone Joint Surg Am* 2008;90:962-969.)

- La curación comienza con la formación de un tejido fibrovascular entre el tendón y el hueso
- Estudios demuestran que la formación de fibras de colágeno es mayor cuanto mayor sea el área de contacto entre el tendón y el hueso.
- Este trabajo proporciona las bases anatómicas del beneficio de la doble hilera.

21. Oguma H, Murakami G, Takahashi-Iwanaga H, Aoki M, Ishii S: Early anchoring collagen fibers at the bonetendon interface are conducted by woven bone formation: Light microscope and scanning electron microscope observation using a canine model. *J Orthop Res* 2001;19:873-880.

- Fracaso biológico:
 - Cirugía de revisión
 - Paciente fisiológicamente anciano
 - Fumador
 - Múltiples infiltraciones corticoides
 - Diabetes, problemas vasculares
 - Infiltración grasa

25. Rudzki JR, Adler RS, Warren RF, et al: Contrast-enhanced ultrasound characterization of the vascularity of the rotator cuff tendon: Age- and activityrelated changes in the intact asymptomatic rotator cuff. *J Shoulder Elbow Surg* 2008;17(1 suppl):96S-100S.

- Fracaso anatómico:

- Introducción concepto de “footprint restoration” en la reparación del manguito.
- Determinan que el área de contacto con una sutura transósea es un 20% mayor que con una sutura en una hilera.

26. Apreleva M, Ozbaydar M, Fitzgibbons PG, Warner JJ: Rotator cuff tears: The effect of the reconstruction method on three-dimensional repair site area. *Arthroscopy* 2002;18:519-526.

- El área de contacto en una doble hilera es 42% mayor que con una sutura transósea y 60% mayor

27. Tuoheti Y, Itoi E, Yamamoto N, et al: Contact area, contact pressure, and pressure patterns of the tendon-bone interface after rotator cuff repair. *Am J Sports Med* 2005;33:1869-1874.

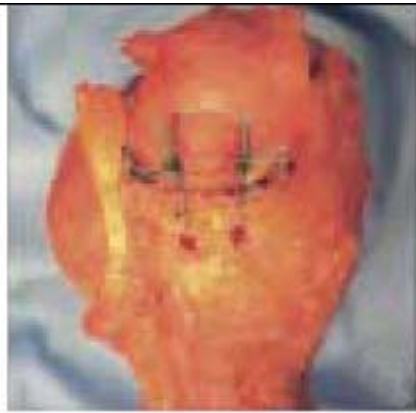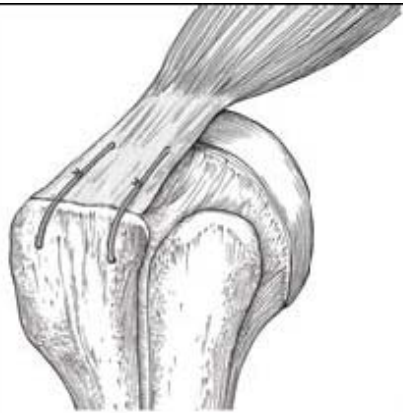- **Fracaso anatómico**

28. Mazzocca AD, Millett PJ, Guanche CA, Santangelo SA, Arciero RA: Arthroscopic single-row versus double row suture anchor rotator cuff repair. *Am J Sports Med* 2005;33:1861-1868.

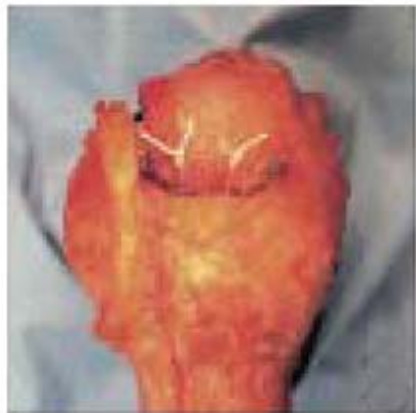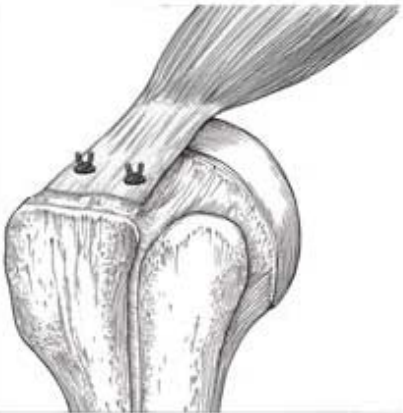
– Demuestran que la doble hilera restaura un “footprint” mayor que las construcciones en hilera simple.

14. Meier SW, Meier JD: Rotator cuff repair: The effect of double-row fixation on three-dimensional repair site. *J Shoulder Elbow Surg* 2006;15:691-696.

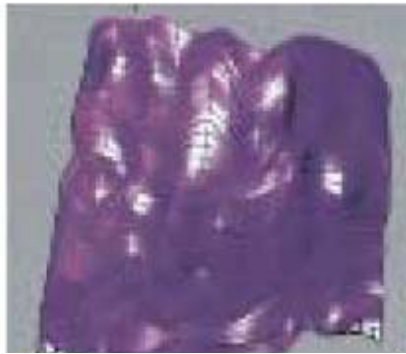
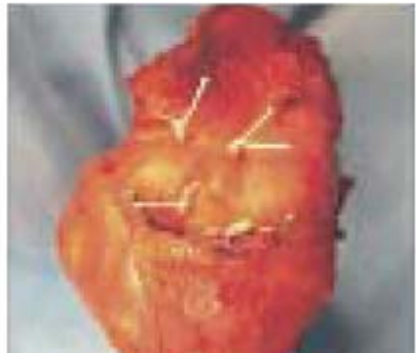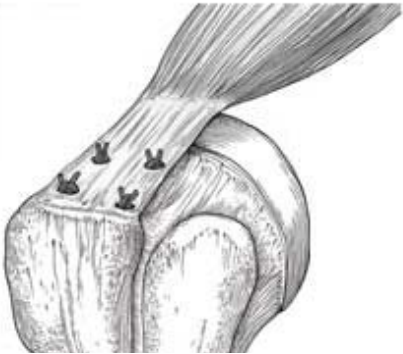– Usando mapas tridimensionales demuestran que las configuraciones en doble hilera recrean el 100% del “footprint” original, mientras que las técnicas transóseas reproducen el 71% y las hileras simples el 46%.



A



B



- **Presión en la interfase hueso-tendón**
 - Las fuerzas controladas en la interfase afectan a la curación
 - Estudios en cadáver demuestran que las hileras simples producen menos presión en el área de contacto que otras técnicas

30. Park MC, Cadet ER, Levine WN, Bigliani LU, Ahmad CS: Tendon-to-bone pressure distributions at a repaired rotator cuff footprint using transosseous suture and suture anchor fixation techniques. *Am J Sports Med* 2005;33: 1154-1159.

31. Park MC, ElAttrache NS, Tibone JE, Ahmad CS, Jun BJ, Lee TQ: Part I: Footprint contact characteristics for a transosseous-equivalent rotator cuff repair technique compared with a double-row repair technique. *J Shoulder Elbow Surg* 2007;16:461-468.

- Fracaso mecánico

- La fuerza a nivel de la inserción del SE varia entre 175 y 900 N si la lesión afecta al infraespinoso.

- Estas fuerzas aumentan en las rotaciones

7. Gerber C, Schneeberger AG, Beck M, Schlegel U: Mechanical strength of repairs of the rotator cuff. *J Bone Joint Surg Br* 1994;76:371-380.

- La fuerza de fracaso de una hilera simple es de 273 N aumentando a 336 con una segunda hilera.

- Construcciones mecánicamente más fuertes pueden proteger la reparación durante las primeras fases del proceso de curación

- **Fracaso mecánico.**

36. Milano G, Grasso A, Zarelli D, Deriu L, Cillo M, Fabbriciani C: Comparison between single-row and double-row rotator cuff repair: A biomechanical study. *Knee Surg Sports Traumatol Arthrosc* 2008;16:75-80.

– Las suturas en una hilera presentan mayor debilidad cuando están hechas a tensión, la cual es mejor resistida por los montajes en doble hilera.

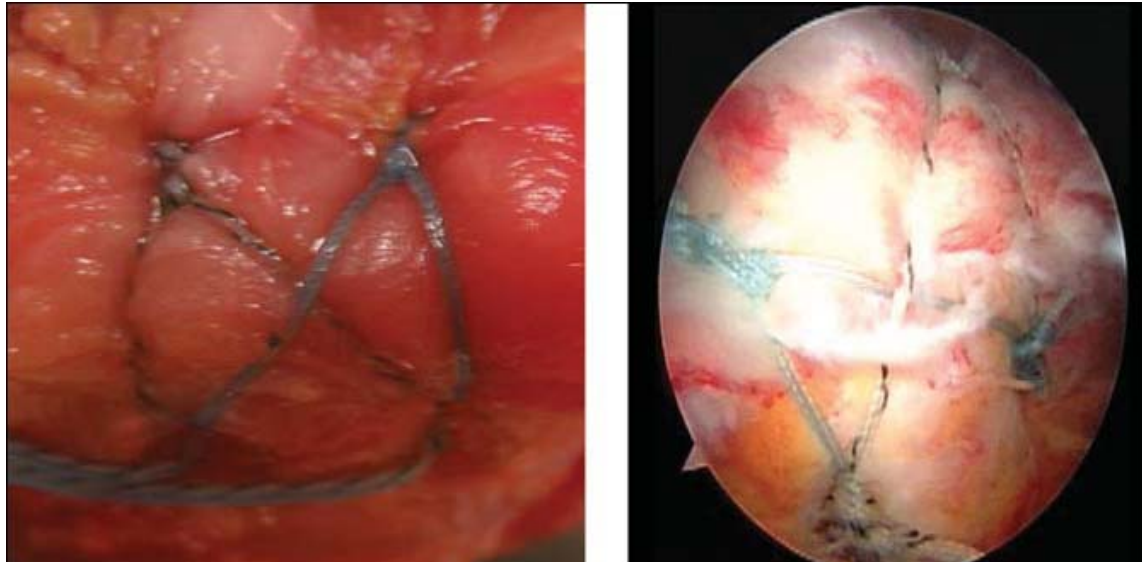
28. Mazzocca AD, Millett PJ, Guanche CA, Santangelo SA, Arciero RA: Arthroscopic single-row versus double row suture anchor rotator cuff repair. *Am J Sports Med* 2005;33:1861-1868.

34. Mahar A, Tamborlane J, Oka R, Esch J, Pedowitz RA: Single-row suture anchor repair of the rotator cuff is biomechanically equivalent to doublerow repair in a bovine model. *Arthroscopy* 2007;23:1265-1270.

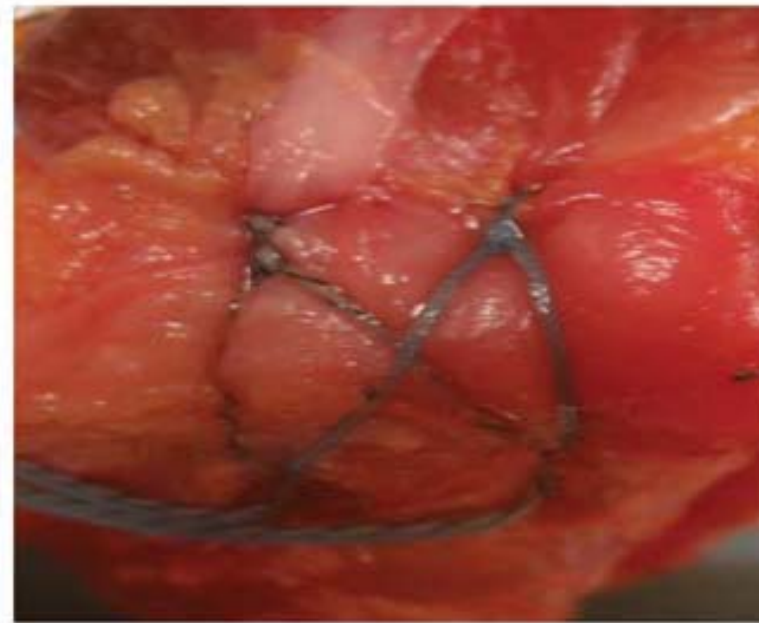
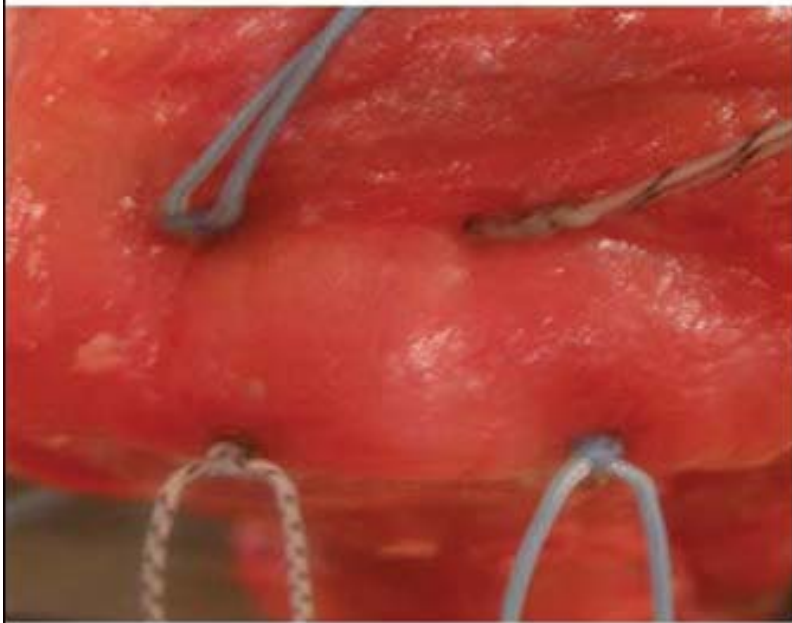
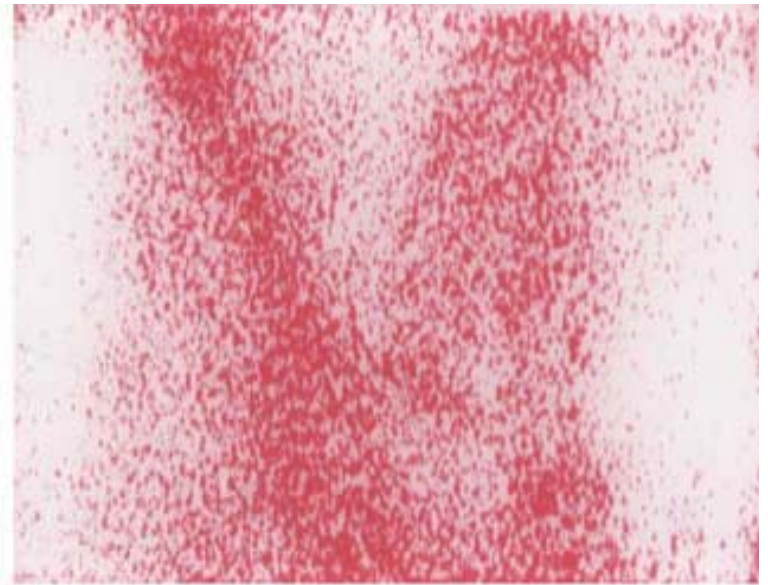
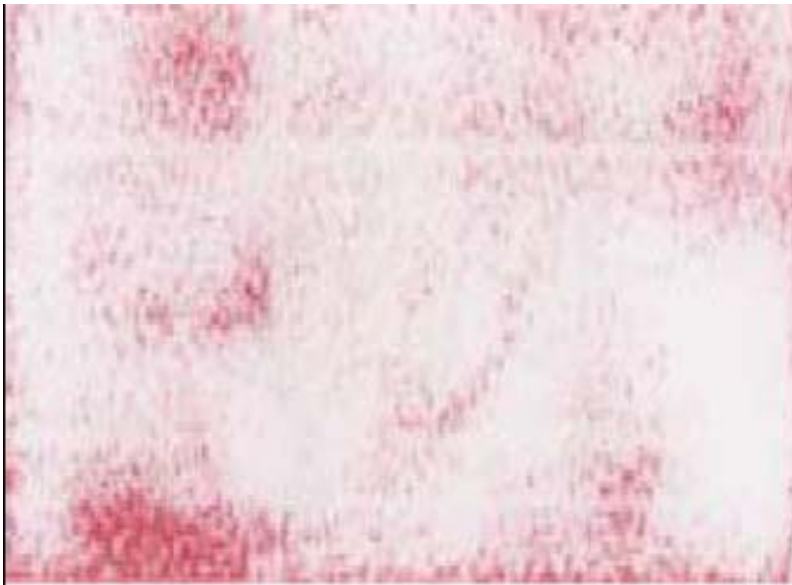
– No encuentran diferencias entre hileras simples y dobles en cuanto al fracaso mecánico.

- “Suture bridge” – “Transosseous-equivalent”

9. Park MC, ElAttrache NS, Ahmad CS, Tibone JE: Transosseous equivalent” rotator cuff repair technique. *Arthroscopy* 2006;22:1360.e1-5.



– Esta técnica recrea la presión en toda la zona de contacto que se obtiene por técnicas transóseas



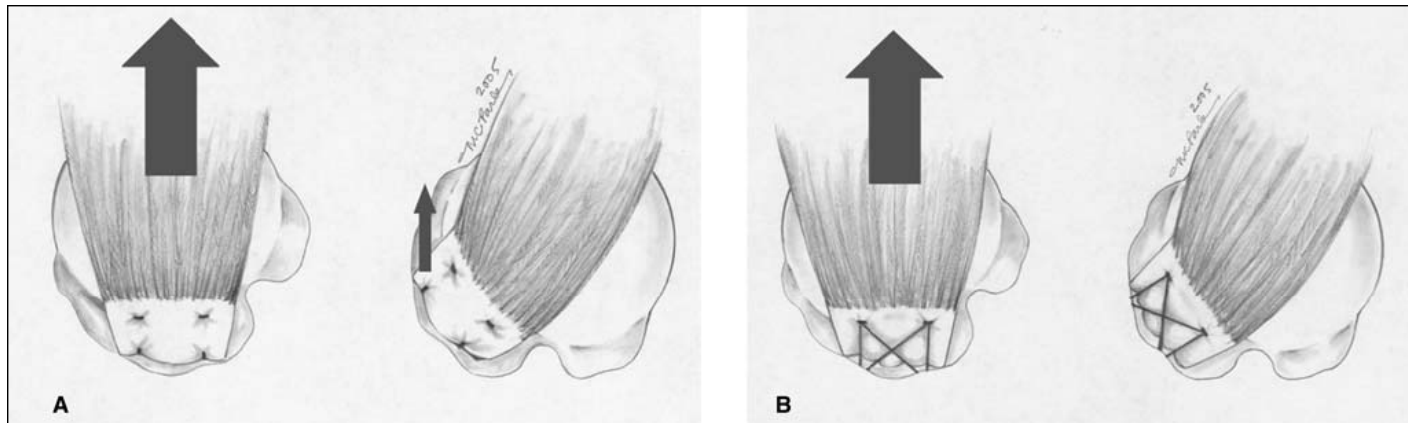
A

B

- “Suture bridge” – “Transosseous-equivalent”

37. Park MC, Idjadi JA, ElAttrache NS, Tibone JE, McGarry MH, Lee TQ: The effect of dynamic external rotation comparing 2 footprint-restoring rotator cuff repair techniques. *Am J Sports Med* 2008;36:893-900.

38. Park MC, Tibone JE, ElAttrache NS, Ahmad CS, Jun BJ, Lee TQ: Part II: Biomechanical assessment for a footprint-restoring transosseousequivalent rotator cuff repair technique compared with a double-row repair technique. *J Shoulder Elbow Surg* 2007; 16:469-476.



- Resultados clínicos

- La mayoría de los estudios presentados son en cadáver. No incluyen los periodos de curación del tendón ni los factores biológicos y vasculares del proceso.
- Las técnicas de doble hilera también tienen problemas teóricos: aumento tiempo de cirugía, aumento del coste. Lesiones en las tuberosidades por el aumento de implantes usados.
- Se precisan estudios clínicos para comparar los resultados entre las técnicas.

39. Franceschi F, Ruzzini L, Longo UG, et al: Equivalent results of arthroscopic single-row and double-row suture anchor repair for rotator cuff tears: A randomized controlled trial. *Am J Sports Med* 2007;35:1254-1260.

- Estudio nivel I. 60 pacientes con rotura reparable. Evaluación a los 2 años de la cirugía. Escala UCLA y artroRMN. No diferencias en función, movilidad y curación según resonancia.

40. Burks RT, Crim J, Brown N, Fink B, Greis PE: A prospective randomized clinical trial comparing arthroscopic single- and double-row rotator cuff repair: Magnetic resonance imaging and early clinical evaluation. *Am J Sports Med* 2009;37:674-682.

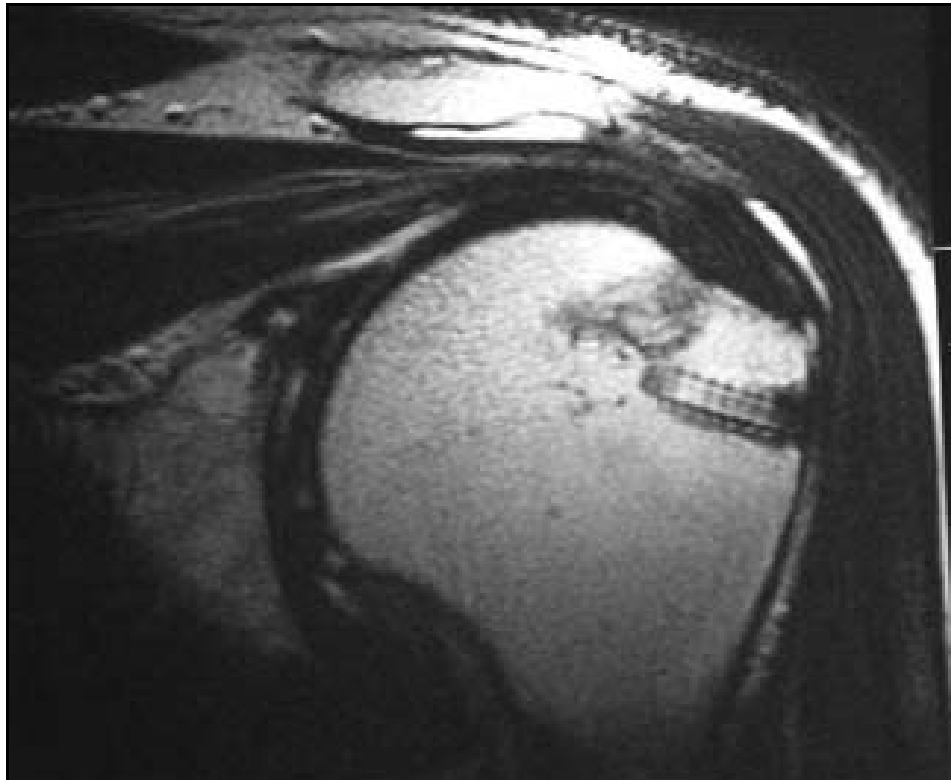
- 40 pacientes. La RMN muestra no diferencias en cobertura del footprint, grosor del tendón o señal tendinosa. Los resultados clínicos son similares en ambos grupos.

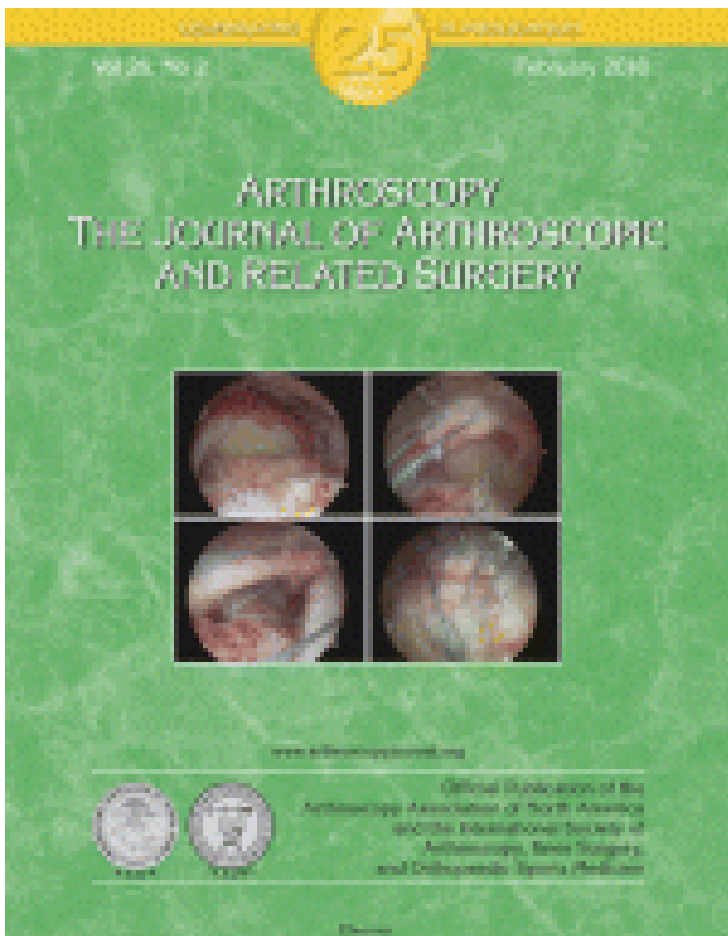
41. Grasso A, Milano G, Salvatore M, Falcone G, Deriu L, Fabbriciani C: Single-row versus double-row arthroscopic rotator cuff repair: A prospective randomized clinical study. *Arthroscopy* 2009;25:4-12.
- Estudio nivel I. 80 pacientes. No diferencias significativas a los 2 años.
42. Charouset C, Grimberg J, Duranthon LD, Bellaiche L, Petrover D: Can a double-row anchorage technique improve tendon healing in arthroscopic rotator cuff repair? A prospective, nonrandomized, comparative study of double-row and single-row anchorage techniques with computed tomographic arthrography tendon healing assessment. *Am J Sports Med* 2007;35:1247-1253.
- Mayor incidencia de curación en doble hilera. No diferencias clínicas.

43. Sugaya H, Maeda K, Matsuki K, Moriishi J: Functional and structural outcome after arthroscopic full-thickness rotator cuff repair: Single-row versus dual-row fixation. *Arthroscopy* 2005;21: 1307-1316.
- Retrospectivo 35 meses. No diferencias en resultados subjetivos. La RMN postoperatorio muestra mayor tasa de curación con doble hilera.
44. Sugaya H, Maeda K, Matsuki K, Moriishi J: Repair integrity and functional outcome after arthroscopic double-row rotator cuff repair: A prospective outcome study. *J Bone Joint Surg Am* 2007;89:953-960.
- Prospectivo 86 pacientes. Resultados funcionales evaluados a los 31 meses de media. Mejoría significativa al final del seguimiento. 17% rerotura más frecuente en pacientes con roturas grandes o masivas (40% recurrencia)

4. Lafosse L, Brozka R, Toussaint B, Gobezie R: The outcome and structural integrity of arthroscopic rotator cuff repair with use of the double-row suture anchor technique. *J Bone Joint Surg Am* 2007;89:1533-1541.
- Prospectivo 105 pacientes. Mejoría del Constant a los 23 meses. 11% re-roturas
45. Park JY, Lhee SH, Choi JH, Park HK, Yu JW, Seo JB: Comparison of the clinical outcomes of single- and doublerow repairs in rotator cuff tears. *Am J Sports Med* 2008;36:1310-1316.
- Mejoría clínica en ambos grupos, pero no encuentran diferencias significativas. Si se encuentran mejorías clínicas en el subgrupo de roturas mayores de 3 cm.

5. Frank JB, ElAttrache NS, Dines JS, Blackburn A, Crues J, Tibone JE: Repair site integrity after arthroscopic transosseous-equivalent suture-bridge rotator cuff repair. *Am J Sports Med* 2008;36:1496-1503.
- Primer trabajo sobre el “suture bridge”. 25 pacientes. 88% curación al año





Systematic Review

Clinical Outcomes of Double-Row Versus Single-Row Rotator Cuff Repairs

Lindley B. Wall, M.D., Jay D. Keener, M.D., and Robert H. Brophy, M.D.,

Purpose: The purpose of this review was to determine whether there is a difference in the clinical outcome between single-row and double-row rotator cuff repairs. **Methods:** We performed a systematic review of the results of clinical studies investigating and comparing double-row and single-row repair techniques. The articles meeting the inclusion and exclusion criteria were assessed for quality of the study; the results were then reviewed to provide a concise conclusion regarding the clinical outcomes of double-row versus single-row rotator cuff repair. **Results:** There were 3 Level I studies and 2 Level II studies comparing the clinical outcomes of double-row and single-row rotator cuff repair. At 1-year follow-up, there was no statistically significant clinical difference between patients who had undergone double-row repair and those who had undergone single-row rotator cuff repair. **Conclusions:** Arthroscopic rotator cuff repairs with double-row repair show no significant difference compared with single-row repair in clinical outcome at 1-year follow-up. Additional prospective, randomized controlled trials are needed with longer-term follow-up to determine whether there is any clinical difference between the 2 techniques. **Level of Evidence:** Level II, systematic review of Level I and II studies. **Key Words:** Double-row repair—Single-row repair—Rotator cuff tear—Clinical—Systematic review—Outcome.

1312 Arthroscopy: The Journal of Arthroscopic and Related Surgery, Vol 25, No 11 (November), 2009: pp 1312-1318

- Propósito: Determinar si existen diferencias en los resultados clínicos entre la doble hilera y la sencilla.
- Método: Revisión sistemática de artículos científicos.
- Resultados: 3 estudios nivel I y 2 nivel II. A un año de seguimiento no hay diferencias estadísticamente significativas entre los pacientes tratados con sutura en doble hilera y los tratados con hilera simple.
- Se necesitan estudios con más tiempo de evolución.

TABLE 1. *Summary of Demographics for Clinical Studies*

| Author | No. of Patients | Mean Age (Range) (yr) | Position | Surgical Technique |
|---------------------------------|------------------|--------------------------------------|----------------------|---|
| Burks et al. ²² | SR, 20 DR, 20 | SR, 56 (43-74) DR, 57 (41-81) | Beach chair | SR, Bio FT anchors (Arthrex) DL simple DR, Bio FT anchors DL mattress medial, simple lateral |
| Charousset et al. ¹⁸ | SR, 35 DR, 31 | SR, 58 (32-74) DR, 60 (37-62) | Beach chair | SR, Panalok RC (DePuy Mitek) SL simple DR, Cuff Tack (DePuy Mitek) medial, Panalok RC SL simple lateral |
| Franceschi et al. ²⁰ | SR, 26 DR, 26 | SR, 63.5 (43-76) DR, 59.6 (45-80) | Lateral decubitus | SR, Bio-Corkscrew (Arthrex) DL mattress DR, Bio-Corkscrew DL mattress medial, simple lateral |
| Grasso et al. ²¹ | SR, 37 DR, 35 | SR, 58.3 ± 10.3 DR, 55.2 ± 6.5 | Beach chair | SR, Corkscrew anchor DL simple DR, Corkscrew anchor DL mattress medial, simple lateral |
| Park et al. ¹⁹ | SR, 40 DR, 38 | SR, 57 (39-78) DR, 54.4 (28-76) | Beach chair | SR, TwinFix (Smith & Nephew Endoscopy) and Super Revo (ConMed Linvatec) alternating DR, TwinFix medial, Super Revo lateral |

Abbreviations: DL, double-loaded anchor; SL, single-loaded anchor.

TABLE 2. *Summary of Clinical Results*

| Author | Mean Follow-up (mo) | No. of Patients Lost to Follow-up | Constant Score | Clinical Outcome Measures | Radiographic Outcome Measures |
|------------------------------------|--|-----------------------------------|--------------------------------------|--|--|
| Burks et al. ²² | 12 | 0 | SR, 77.8 DR, 74.4 | WORC, ASES, UCLA, SANE, ER, IR | MRI to assess footprint, thickness and signal content |
| Charoussat et al. ¹⁸ | SR, 27.6 (range, 24-37.7) DR, 28.7 (range, 24-40) | SR, 2 DR, 3 | SR, 80.7 DR, 82.7 | Objective evaluation, subjective evaluation, time to return to work | Computed tomography arthrography* |
| Franceschi et al. ²⁰ | 22.5 (range, 18-25) | SR, 4 DR, 4 | | UCLA, FF, ER, IR | Magnetic resonance arthrography to assess cuff integrity |
| Grasso et al. ²¹ | 24.8 ± 1.4 | SR, 3 DR, 5 | SR, 100.5 ± 17.8 DR, 104.9 ± 21.8 | DASH, work DASH, strength | |
| Park et al. ¹⁹ | 25.1 (range, 22-30) | SR, 3 DR, 4 | SR, 76.7 ± 8.6 DR, 79.7 ± 4.5† | ASES index,‡ SSI (abduction, IR, ER) | |

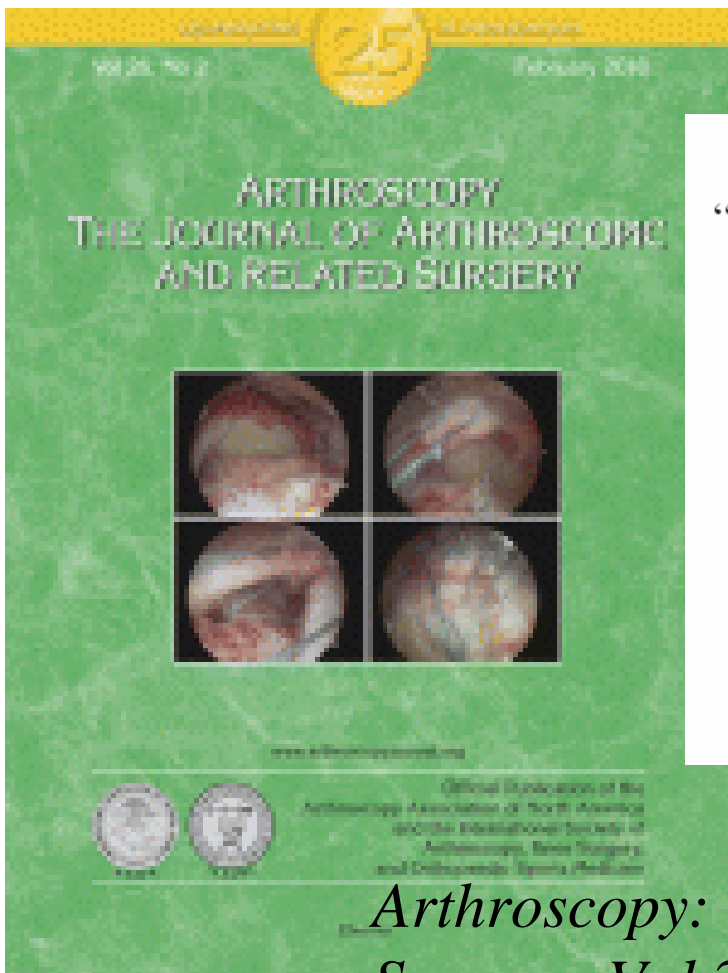
Bibliografía

19. Park JY, Lhee SH, Choi JH, Park HK, Yu JW, Seo JB. Comparison of the clinical outcomes of single- and double-row repairs in rotator cuff tears. *Am J Sports Med* 2008;36:1310-1316.
20. Franceschi F, Ruzzini L, Longo UG, et al. Equivalent clinical results of arthroscopic single-row and double-row suture anchor repair for rotator cuff tears: A randomized controlled trial. *Am J Sports Med* 2007;35:1254-1260.
21. Grasso A, Milano G, Salvatore M, Falcone G, Deriu L, Fabriciani C. Single-row versus double-row arthroscopic rotator cuff repair: A prospective randomized clinical study. *Arthroscopy* 2009;25:4-12.
22. Burks RT, Crim J, Brown N, Fink B, Greis PE. A prospective randomized clinical trial comparing arthroscopic single- and double-row rotator cuff repair. *Am J Sports Med* 2009;37:647-683.
23. Sugaya H, Maeda K, Matsuki K, Moriishi J. Functional and structural outcome after arthroscopic full-thickness rotator cuff repair: Single-row versus dual-row fixation. *Arthroscopy* 2005;21:1307-1316.

Does the literature support double-row suture anchor fixation for arthroscopic rotator cuff repair? A systematic review comparing double-row and single-row suture anchors configuration.

Nho SJ, Romeo AA. Arthroscopy. 2009 Nov;25(11):1319-28

Mismos resultados.



Technical Note

“Transosseous-Equivalent” Rotator Cuff Repair Technique

Maxwell C. Park, M.D., Neal S. ElAttrache, M.D., Christopher S. Ahmad, M.D.,
and James E. Tibone, M.D.

Abstract: In order to optimize healing biology at a repaired rotator cuff footprint, we have developed a “transosseous-equivalent” rotator cuff repair that can be performed arthroscopically. What the arthroscopically repaired tendon experiences is “equivalent” to what is experienced with a traditional open suture-bridge technique. This repair maximizes the utility of a single-row repair technique by preserving the suture limbs of the medial single-row and bridging these sutures over the footprint insertion with distal-lateral interference screw suture fixation; the medial row uses a mattress suture configuration. The geometry of the construct compresses the tendon, optimizing tendon-to-tuberosity contact dimensions, while providing strength sufficient to withstand immediate postoperative rehabilitation. **Key Words:** Rotator cuff—Footprint—Transosseous-equivalent—Suture-bridge—Double-row.

Arthroscopy: The Journal of Arthroscopic and Related Surgery, Vol 22, No 12 (December), 2006: pp 1360.e1-1360.e5

Abstract: Con el objeto de mejorar la curación biológica de un manguito rotador reparado hemos desarrollado una reparación “equivalente transóseo” que puede realizarse artroscópicamente. La geometría de la construcción comprime el tendón contra su zona de inserción, optimizando la dimensión del contacto entre el tendón y la tuberosidad, proporcionando un resisencia a la tracción óptima y permitiendo la rehabilitación precoz.

TABLE 1. Recommended Repair Technique Based on Full-Thickness Tear Size, Anterior-to-Posterior, on Greater Tuberosity Supraspinatus Footprint, With Considerations for Ultimate Load-to-Failure and Footprint Contact Dimensions

| Anterior-to-Posterior Tear Size | Type of Repair (Relative Indication) |
|---------------------------------|---|
| 6 mm, <25% | Single anchor or row |
| 12 mm, <50% | Single-row (relatively small greater tuberosity), double-row, or transosseous-equivalent 2 suture bridge (poor lateral tendon tissue) |
| 18 mm, <75% | Transosseous-equivalent 2 or 4 suture bridge (infraspinatus involved on greater tuberosity) |
| 24 mm, 100% | Transosseous-equivalent 4 suture bridge |

